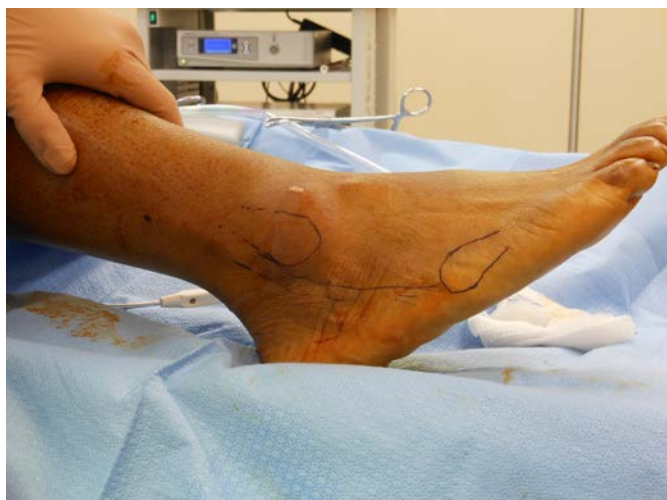

# *Large Osteochondral Defect Case Using NuCel*

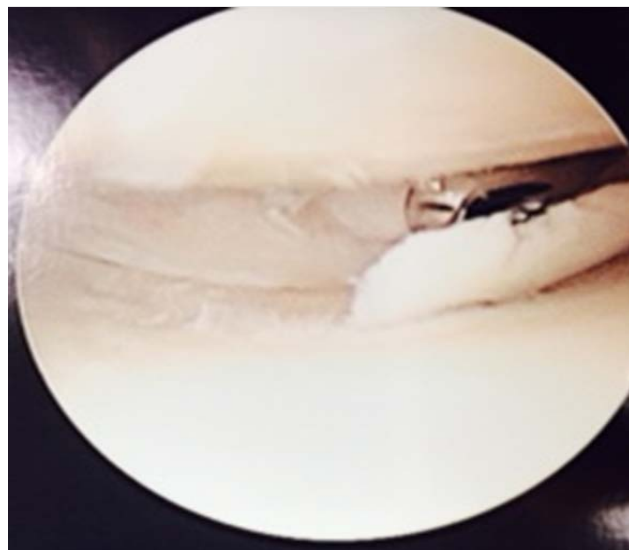
*J. Joseph Anderson, DPM  
New Mexico Bone and Joint Institute*

---

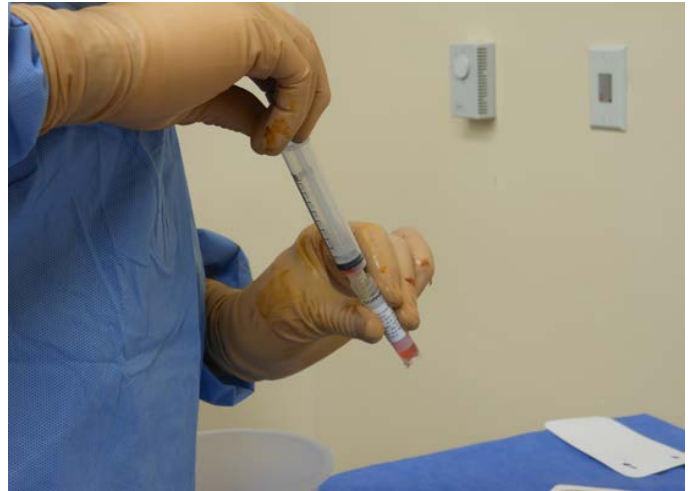29 year old male with pain in the right foot and ankle. He sustained a previous peroneal tendon tear. He complains of right ankle pain after he finishes his runs.



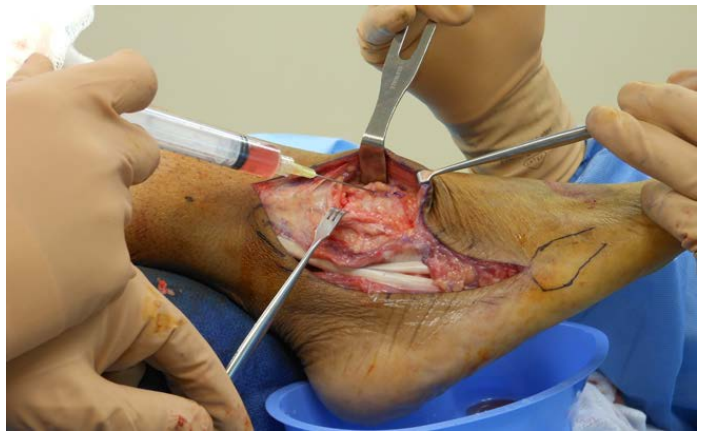Patient had a right ankle arthroscopy with debridement of OCD with talar allografting including microfracture.



NuCel human amniotic allograft (HAA) was used for osteochondral grafting post OCD microfracture.



Peroneal tendons were repaired.



Patient is nine weeks postop back to full activity.

