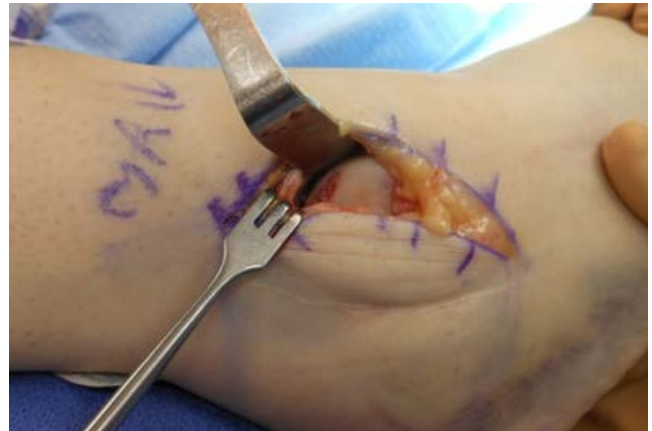

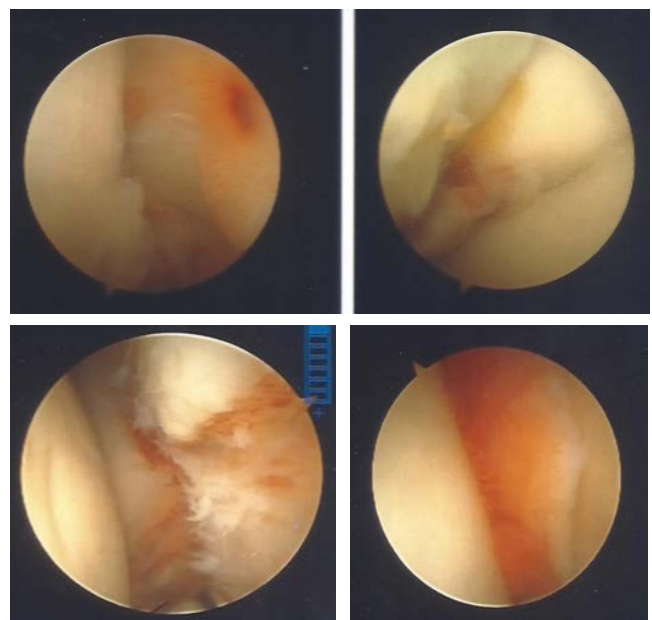
## *Osteochondral Defect-Athlete Using NuShield and NuCel*

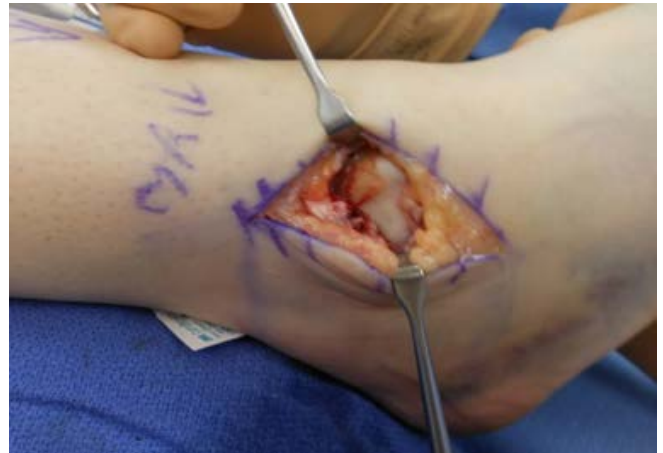*J. Joseph Anderson, DPM  
New Mexico Bone and Joint Institute*

Patient is 23 year old college soccer player; she rolled her ankle and heard a “snap.” She has a history of ankle ligament repair and drilling of osteochondral defect.

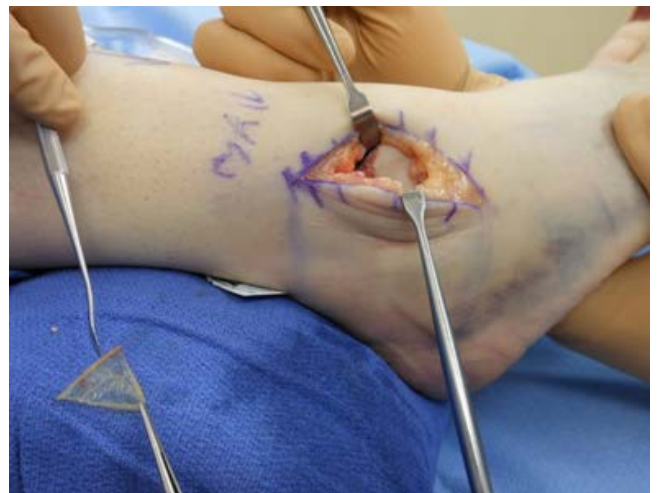

She was treated conservatively with no improvement. The decision was made to perform ankle arthroscopy (to reach the posterior and medial joint) with debridement of synovitis and osteochondral lesion.





NuShield (folded and onlayed) and NuCel (solution) human amniotic allografts were positioned into the ankle and held in place with fibrin glue. Lateral ankle ligaments were also repaired.



The patient was back to normal activity and had returned to running within 4 months of surgery. At 24 months, she had no pain and full range of motion, doing full activity.

